

[Original Article]

28-day Repeated Dose Oral Toxicity Test of *Coix lacryma-jobi* L. var. *ma-yuen* Stapf in Rats

Hiroataka HAYASHI^{1,2,*}, Takanari ARAI³, Jeffrey M. STRONG², Harukuni TOKUDA²,
Yasuko SHIMANO⁴, Yasuyuki OHTA⁴, Toshiki ENOMOTO⁵, Kazuo UEBABA⁶,
Tomihisa OHTA⁴, Nobutaka SUZUKI²

¹ Center for Innovation, Kanazawa University

² Department of Complementary and Alternative Medicine Clinical Research and Development, Kanazawa University

³ Endowed Center for the Advancement of Pregnancy, Perinatal and Infant Care,
Kanazawa University Graduate School of Medical Science

⁴ Graduate School of Natural Science and Technology, Kanazawa University

⁵ Department of Food Science, Ishikawa Prefectural University

⁶ Department of Presymptomatic Health Promotion Institute of Natural Medicine, University of Toyama

[ABSTRACT]

Coix lacryma-jobi L. var. *ma-yuen* Stapf (coix seed) is a grass crop that has long been used in traditional medicine as a nourishing food. However, high-intake safety of the extract of the husks, pellicles and astringent skin of coix seed has rarely been evaluated. We performed a 28-day repeated dose oral toxicity test of hot water extract of all parts of Coix seed in rats. The extract showed no significant toxicity on body weight, blood analyses, urinalysis and histopathological examination in acute toxicity tests.

[Key words]

Coix lacryma-jobi L. var. *ma-yuen* Stapf, Coix seed, safety test, subacute toxicity test, rat

1. INTRODUCTION

A grain with the husk [scientific name: seed] of a coix seed (also known as *adlay*, *job's tears*, or *pearl barley*) belonging to the genus coix of the family Poaceae [scientific name: *Coix lacryma-jobi*, L. var. *ma-yuen* (Roman.) Stapf] is composed of, from the outermost to innermost layer: a husk [scientific name: involucre], a pellicle [scientific name: glume, palea, and lemma] and astringent skin (bran) [scientific name: caryopsis] (Fig. 1). We invented a composition for foods or medicaments containing hot water extracts of the husks, pellicles and astringent skin of coix seed. The pharmaceutical composition is expected to have an anti-neoplastic effect, anti-human

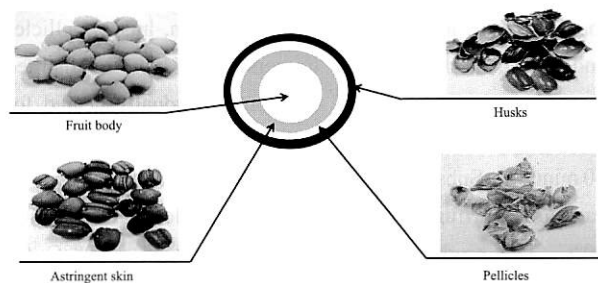


Fig. 1 Structure of *Coix lacryma-jobi* L. var. *ma-yuen* Stapf (Coix seed)

Accepted Date: August 19, 2009

* Center for Innovation, Kanazawa University, Kakumamachi Kanazawa, Ishikawa 920-1164, Japan Tel: +81-76-265-2147

Fax: +81-76-234-4247 E-mail: euglenal234@yahoo.co.jp

copyright(c) 2010 産学連携品電子図書館 all right reserved

papillomaviral diseases effect, and effect against various cutaneous diseases (or the like), such that it is useful for chemoprophylaxis or therapy against tumors, and for preventing or treating human papillomaviral diseases such as condyloma acuminatum, verruca vulgaris, adolescent verruca, senile verruca or laryngeal papillomatosis.

In the preliminary toxicity test of dehulled coix seed (yokuinin), it was reported that the administration of a powder diet containing 5% by weight yokuinin to pregnant rats revealed no treatment-related effects on birth index, viability indices, sex ratio, body weight or gross pathological findings¹⁾. Acute oral toxicity test in rats revealed that the hot water extract of all parts of coix seed is safe²⁾. However, to the best of our knowledge, a 28-day repeated dose oral toxicity test of this extract has not been performed. We therefore performed a safety test of hot water extract of all parts of coix seed on rats.

2. MATERIALS AND METHODS

2.1 Production of extract of husks, pellicles and astringent skin of coix seed

Hot water extract of husks, pellicles, astringent skin and grains of coix seed produced by CRD Co., Ltd (Ishikawa, Japan) was used for the test article. Hot water extract of husks, pellicles and astringent skin of Coix seed can be obtained through various methods. Specifically, Coix seed with husks (grains with husks) are washed well with distilled water and dried. Husks are then lightly ground with a rice-milling machine. After dehulling, Coix seed grains are separated into unde-hulled and dehulled grains using a sieve with a mesh size of approximately 3.5 (5.6 mm). Undehulled grains are remilled to obtaining husks, pellicles or astringent skin. At this point, it is necessary to adjust the strength of the milling machine so that the grains are not broken. 1 kg of grain, husks, pellicles and astringent skin are then immersed in 7 liters of distilled water for 1 hour. Next, this solution is gradually heated for 60 minutes to boiling point, followed by further boiling for 60 minutes. Subsequently, the solution is concentrated by vacuum centrifugation for 60 minutes while heating at 40–50°C. The product is then cooled, sterilized at 98°C for 30 minutes, and dried by spray-dry method.

2.2 Test animal and housing conditions

Experimental procedures were approved by the Animal Care and Use Committee of Kanazawa University, Kanazawa, Japan.

Male (n=10) and female (n=10) 8-week old Wister rats were

obtained from Charles River Japan Inc., Japan (Kanagawa, Japan). Rats were kept in a room maintained at controlled temperature (25±2°C), humidity (60±10%), and lighting (9:00 to 21:00 hours) and 3 or 4 rats were housed in one cage. The animals were given free access to solid feed (CRF-1, Oriental Yeast Co., Ltd.) and tap water.

2.3 Group condition and dose levels

When rats were 9-weeks old, the test article was administered at a daily dose of 0, 500, and 2,000 mg/kg (male n=10, female n=10). The test article was dissolved in distilled water and injected intragastrically by direct stomach intubation. After 28 day administration, rats were sacrificed and subjected to blood collection and necropsy.

2.4 Observation of general condition and body weight

General condition was monitored twice daily (morning and afternoon) for 28 days.

Body weight was measured every day for 28 days.

2.5 Necropsy finding and organ weight measurement

On day 29, all animals were sacrificed and subjected to necropsy. The following organs were removed and weighed: brain, thyroids, heart, lungs, thymus, liver, spleen, kidneys, testes, seminal vesicle, ovaries and uterus.

2.6 Histopathological examination

In the control and high-dose groups (2,000 mg/kg), histopathological examination was made of the following organs: brain, pituitary, accessory thyroid, thyroid, heart, thymus, lung, liver, spleen, kidney, adrenal gland, testes, gonocyst, epididymis, uterus and ovaries. All samples were fixed in 10% neutral buffer formalin and stained with hematoxylin-eosin. Manufacture of specimens was performed by the Department of Pathology, Kanazawa University Hospital.

2.7 Hematology

Blood was collected into a tube with EDTA-2K and examined for white blood cell count (WBC), red blood cell count (RBC), hemoglobin content, hematocrit value, mean corpuscular volume (MCV), mean corpuscular hemoglobin (MCH), mean corpuscular hemoglobin concentration (MCHC), blood platelet, neutrophil, eosinophil, basophil, monocyte and lymphocyte. All measurements were performed by SRL Co., Ltd (Tokyo, Japan).

2.8 Blood biochemistry

The following analyses were also performed by SRL Co., Ltd.: total protein, albumin, aspartate aminotransferase (AST), alanine aminotransferase (ALT), alkaline phosphatase (ALP), γ -GTP, total bilirubin, total cholesterol, neutral lipid, HDL-cholesterol, LDL-cholesterol, blood urea nitrogen (BUN), creatinine, Na, Cl, K and glucose (blood serum).

2.9 Urinalysis

Urine was collected before euthanasia. Hidden blood, glucose, and protein levels in urea were qualitatively analyzed using urine test paper obtained from WAKO, Co., Ltd., (Osaka, Japan).

2.10 Statistical analysis

Data obtained from the 28-day repeated dose oral toxicity test were statistically analyzed using Student's *t*-test. One-way

parametric ANOVA with Tukey's test was used to examine body weight, organ weight, hematological and blood biochemistry data.

3. RESULTS AND DISCUSSION

3.1 Observation of general condition and body weight

Administration of the test article revealed no clinical signs, adverse effects or death during the 28-day observation period. Body weight gain was unaffected by the test article during the test period (Fig.2).

3.2 Necropsy findings, organ weight measurement and histopathological examination

No significant changes were observed in any organs at necropsy on day 29 (data not shown). Ovary weight of female rats in the 500 mg/kg test article administration group was

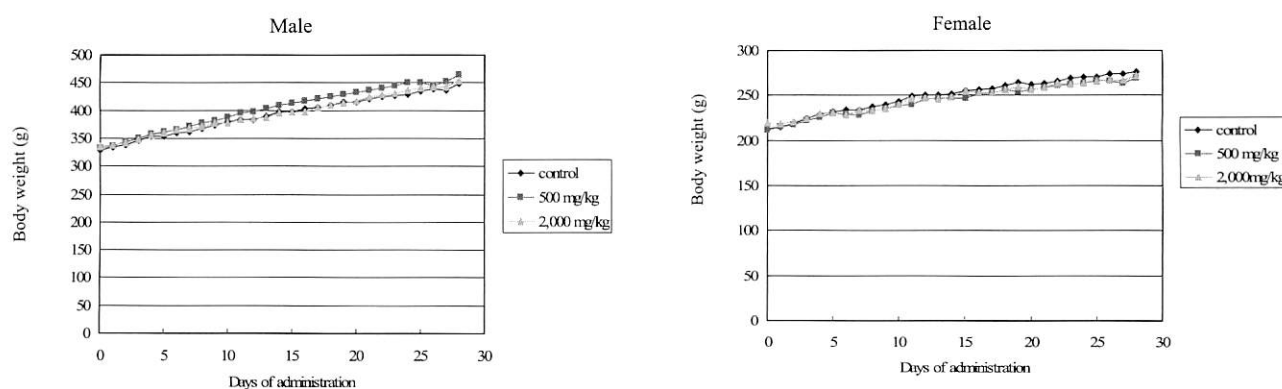


Fig. 2 Body weight change of rats during oral administration of *Coix lacryma-jobi* L.var.*ma-yuen* Stapf over 28 days. 0 mg/kg (male n=10, female n=10), 500 mg/kg (male n=10, female n=10), 2,000 mg/kg (male n=10, female n=10).

Table 1 Organ weights (mean \pm S.D.) in rats after 28 days oral administration of water extract of *Coix lacryma-jobi* L. var.*ma-yuen* Stapf

	Male			Female		
	Control (n=10)	500 mg/kg (n=10)	2,000 mg/kg (n=10)	Control (n=10)	500 mg/kg (n=10)	2,000 mg/kg (n=10)
Brain (g)	1.32 \pm 0.04	1.39 \pm 0.04	1.38 \pm 0.14	1.22 \pm 0.15	1.31 \pm 0.07	1.28 \pm 0.11
Thyroids (mg)	0.77 \pm 0.09	0.78 \pm 0.09	0.78 \pm 0.09	0.54 \pm 0.08	0.51 \pm 0.09	0.52 \pm 0.07
Heart (g)	1.12 \pm 0.10	1.24 \pm 0.10	1.24 \pm 0.20	0.85 \pm 0.07	0.85 \pm 0.09	0.86 \pm 0.07
Lungs (g)	1.49 \pm 0.12	1.57 \pm 0.11	1.52 \pm 0.12	1.26 \pm 0.15	1.22 \pm 0.14	1.22 \pm 0.09
Thymus (g)	0.64 \pm 0.15	0.57 \pm 0.09	0.56 \pm 0.12	0.44 \pm 0.06	0.52 \pm 0.05	0.49 \pm 0.07
Liver (g)	16.60 \pm 1.73	17.92 \pm 1.87	16.97 \pm 2.23	10.96 \pm 1.42	10.06 \pm 0.74	10.00 \pm 0.62
Spleen (g)	1.21 \pm 0.14	1.19 \pm 0.19	1.36 \pm 0.32	0.83 \pm 0.10	0.80 \pm 0.11	0.82 \pm 0.09
Kidneys (g)	2.78 \pm 0.24	3.01 \pm 0.34	2.90 \pm 0.18	1.92 \pm 0.16	1.85 \pm 0.16	1.87 \pm 0.14
Testes (g)	3.68 \pm 0.11	3.71 \pm 0.31	3.84 \pm 0.52	—	—	—
Seminal vesicle (g)	1.28 \pm 0.19	1.41 \pm 0.06	1.30 \pm 0.13	—	—	—
Ovaries (g)	—	—	—	0.65 \pm 0.14	0.45 \pm 0.11*	0.55 \pm 0.18
Uterus (g)	—	—	—	0.22 \pm 0.20	0.20 \pm 0.05	0.20 \pm 0.07

* $p < 0.05$ (compared with control group)

lower than control. However no concentration dependence or histological abnormalities were found in this group. There was no significant difference in other organs (Table 1). Pathological examinations of each organelle revealed no abnormal findings.

3.3 Hematology

The hematocrit value of female rats in the 500 mg/kg test article administration group was higher than control ($p < 0.05$)

(Table 2). However there was no significant difference in concentration dependence.

3.4 Blood biochemistry

AST values of male rats in the 500 and 2,000 mg/kg groups were higher than control. Cl value of female rat in the 500 mg/kg group was lower than control (Table 3). However, there were no significant differences in concentration dependence.

Table 2 Hematological findings (means \pm SD) in rats after 28 days oral administration of water extract of *Coix lacryma-jobi* L. var. *ma-yuen* Stapf

	Male			Female		
	Control (n=10)	500 mg/kg (n=10)	2,000 mg/kg (n=10)	Control (n=10)	500 mg/kg (n=10)	2,000 mg/kg (n=10)
WBC ($10^3/\mu\text{l}$)	9.20 \pm 2.75	7.69 \pm 2.28	9.42 \pm 4.73	4.95 \pm 1.68	5.66 \pm 2.81	5.26 \pm 1.85
RBC ($10^4/\mu\text{l}$)	752.1 \pm 38.8	767.9 \pm 23.8	744.7 \pm 53.9	697.0 \pm 29.3	725.6 \pm 37.9	699.5 \pm 30.3
Hemoglobin content (g/dl)	14.1 \pm 0.7	14.4 \pm 0.6	13.9 \pm 1.2	13.3 \pm 0.5	13.9 \pm 0.8	13.1 \pm 0.5
Hemoglobin value (%)	88.4 \pm 4.4	90.2 \pm 3.6	87.1 \pm 7.4	83.2 \pm 3.1	86.6 \pm 5.3	81.9 \pm 3.2
Hematocrit value (%)	46.1 \pm 2.7	45.6 \pm 1.8	44.2 \pm 3.2	41.8 \pm 2.1	44.7 \pm 3.1*	41.7 \pm 2.7
MCV (fl)	61.4 \pm 2.0	59.3 \pm 1.5	59.4 \pm 1.7	60.0 \pm 2.2	61.6 \pm 2.2	59.6 \pm 3.9
MCH (pg)	18.8 \pm 0.5	18.8 \pm 0.5	18.7 \pm 0.4	19.1 \pm 0.7	19.1 \pm 0.5	18.8 \pm 0.9
MCHC (%)	30.6 \pm 0.7	31.6 \pm 0.3	31.5 \pm 0.9	31.9 \pm 1.0	31.0 \pm 1.1	31.5 \pm 0.9
Blood platelet ($10^4/\mu\text{l}$)	87.3 \pm 9.9	81.3 \pm 11.5	83.4 \pm 16.9	77.2 \pm 13.5	82.3 \pm 9.7	83.1 \pm 11.4
Neutrophils (%)	64.0 \pm 5.3	64.6 \pm 6.2	61.6 \pm 6.8	62.6 \pm 4.7	62.8 \pm 4.5	66.7 \pm 3.2
Eosinophil (%)	1.0 \pm 0.3	1.2 \pm 0.5	2.5 \pm 2.8	3.3 \pm 4.2	1.2 \pm 0.4	1.4 \pm 0.8
Basophil (%)	0.0	0.1 \pm 0.3	0.1 \pm 0.2	0.0	0.0	0.1 \pm 0.3
Monocyte (%)	33.1 \pm 5.7	32.1 \pm 4.8	33.2 \pm 5.6	2.6 \pm 1.5	2.0 \pm 1.6	1.1 \pm 0.9
Lymphocyte (%)	33.2 \pm 6.1	36.6 \pm 2.8	34.3 \pm 9.2	32.1 \pm 6.1	34.1 \pm 4.1	30.6 \pm 3.3

* $p < 0.05$ (compared with control group)

Table 3 Blood biochemical findings (means \pm SD) in rats after 28 days oral administration of water extract of *Coix lacryma-jobi* L. var. *ma-yuen* Stapf

	Male			Female		
	Control (n=10)	500 mg/kg (n=10)	2,000 mg/kg (n=10)	Control (n=10)	500 mg/kg (n=10)	2,000 mg/kg (n=10)
Total protein (g/dl)	5.8 \pm 0.5	5.7 \pm 0.1	5.8 \pm 0.5	5.8 \pm 0.3	5.8 \pm 0.4	5.8 \pm 0.4
Albumin (g/dl)	2.2 \pm 0.2	2.1 \pm 0.0	2.1 \pm 0.1	2.3 \pm 0.2	2.3 \pm 0.2	2.3 \pm 0.2
AST (IU/l)	61.6 \pm 5.8	67.7 \pm 14.6*	68.1 \pm 38.9*	69.9 \pm 23.7	69.9 \pm 15.5	63.3 \pm 6.0
ALT (IU/l)	37.4 \pm 2.0	35.9 \pm 7.2	32.7 \pm 4.4	33.4 \pm 6.3	35.9 \pm 4.4	33.9 \pm 3.8
ALP (IU/l)	98.2 \pm 133.2	161.7 \pm 207.2	249.1 \pm 161.7	244.5 \pm 108.2	192.2 \pm 150.3	204.1 \pm 130.5
γ GTP (IU/l)	1.2 \pm 0.4	1.0 \pm 0.7	1.2 \pm 1.1	0.7 \pm 0.5	0.7 \pm 0.8	0.8 \pm 0.9
Total bilirubin (mg/dl)	0.0 \pm 0.0	0.0 \pm 0.0	0.0 \pm 0.0	0.0 \pm 0.0	0.0 \pm 0.0	0.0 \pm 0.0
Total cholesterol (mg/dl)	67.5 \pm 8.2	63.7 \pm 9.9	59.8 \pm 10.9	62.2 \pm 11.1	68.2 \pm 8.8	62.4 \pm 8.9
Neutral lipid (mg/dl)	144.8 \pm 54.6	122.7 \pm 40.8	109.6 \pm 45.2	64.6 \pm 26.0	88.9 \pm 51.4	58.0 \pm 31.4
HDL-cholesterol (mg/dl)	28.5 \pm 3.6	26.0 \pm 4.0	22.8 \pm 4.7	24.7 \pm 3.6	26.9 \pm 3.1	24.5 \pm 3.6
LDL-cholesterol (mg/dl)	7.4 \pm 2.0	7.7 \pm 1.5	6.7 \pm 2.3	5.3 \pm 1.3	6.2 \pm 1.4	5.6 \pm 1.6
Urea nitrogen (mg/dl)	18.8 \pm 1.6	17.8 \pm 1.4	17.9 \pm 1.8	21.1 \pm 2.7	19.4 \pm 2.2	18.4 \pm 6.2
Creatinin (mg/dl)	0.3 \pm 0.0	0.3 \pm 0.0	0.3 \pm 0.1	0.3 \pm 0.0	0.3 \pm 0.0	0.3 \pm 0.0
Na (mEq/l)	145.8 \pm 3.1	144.2 \pm 2.3	145.0 \pm 1.4	145.2 \pm 1.3	145.7 \pm 2.3	145.0 \pm 1.6
Cl (mEq/l)	97.1 \pm 2.7	98.1 \pm 1.8	99.2 \pm 0.8	102.7 \pm 2.0	99.8 \pm 2.6*	102.8 \pm 1.9
K (mEq/l)	22.2 \pm 9.1	23.1 \pm 14.0	15.2 \pm 3.2	12.5 \pm 3.6	13.5 \pm 3.4	13.6 \pm 3.8
Glucose (blood serum) (mg/dl)	102.3 \pm 32.9	112.1 \pm 32.4	129.6 \pm 75.8	132.1 \pm 20.3	114.6 \pm 39.0	134.1 \pm 39.8

* $p < 0.05$ (compared with control group)

3.5 Urinalysis

Hidden blood, glucose, and protein levels of test groups were not significantly different than control.

4. CONCLUSION

A 28-day repeated dose oral toxicity test of *Coix lacryma-jobi* L. var. *ma-yuen* Stapf in rats revealed that the lethal dose of hot water extract of whole-grain *Coix lacryma-jobi* L. var. *ma-yuen* Stapf is >2000 mg/kg in both male and female rats. The composition of the extract (hot water extract of all parts of coix seed) is derived from natural coix seed, and this

seed has been long used in food preparations, such that we may safely contend that the composition has no (or at least extremely low) toxicity, and thus shows great safety.

REFERENCES

- 1) Shinoda Y, Hirata M, Sato K, et al. Preliminary Reproduction Toxicity Screening Test of *Coix lacryma-jobi* L. var. *ma-yuen* Stapf by Oral Administration in Rats. *Jpn Pharmacol Ther* 2007; 35(1): 67-70.
- 2) Hayashi H, Ohta Y, Arai T, et al. Acute oral toxicity test of hot water extract of *Coix lacryma-jobi* L. var. *ma-yuen* Stapf in rats. *JJCAM* 2009; 6(2): 105-110.

要 旨

ハトムギ熱水抽出物のラット 28 日間反復経口投与毒性試験

林 浩孝^{1,2}, 新井隆成³, Jeffry Michael STRONG², 徳田春邦², 島野康子⁴, 太田康之⁴, 榎本俊樹⁵,
上馬場和夫⁶, 太田富久⁴, 鈴木信孝²

¹金沢大学イノベーション創成センター

²金沢大学大学院医学系研究科臨床研究開発補完代替医療学講座

³金沢大学大学院医学系研究科周生期医療専門医養成学講座

⁴金沢大学大学院自然科学研究科創薬科学講座

⁵石川県立大学食品科学科

⁶富山大学和漢医薬総合研究所

ハトムギの種皮を除いた種子の部分であるヨクイニン[®]は長年、疣贅に対する伝統的な漢方薬として利用されている。しかしながら、ハトムギの殻、薄皮、渋皮の熱水抽出物についての安全性試験に関する報告は少ない。そこで、我々はハトムギの殻、薄皮、渋皮、種子のすべての部分を含む熱水抽出物を高用量 (2,000 mg/kg) 摂取した場合の 28 日間反復経口投与毒性試験をラットを用いて行ったところ、当該エキス摂取後の体重変化、血液検査、臓器重量測定・組織病理検査、尿検査のすべての項目において異常は認められなかった。

キーワード： *Coix lacryma-jobi* L. var. *ma-yuen* Stapf, ハトムギ, 安全性試験, 亜急性毒性試験, ラット